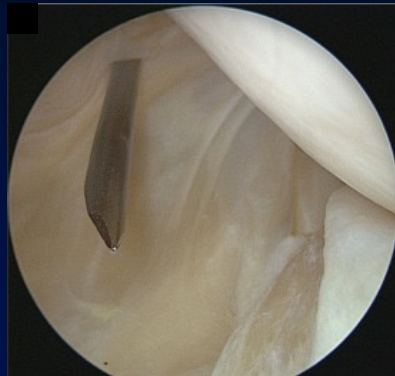

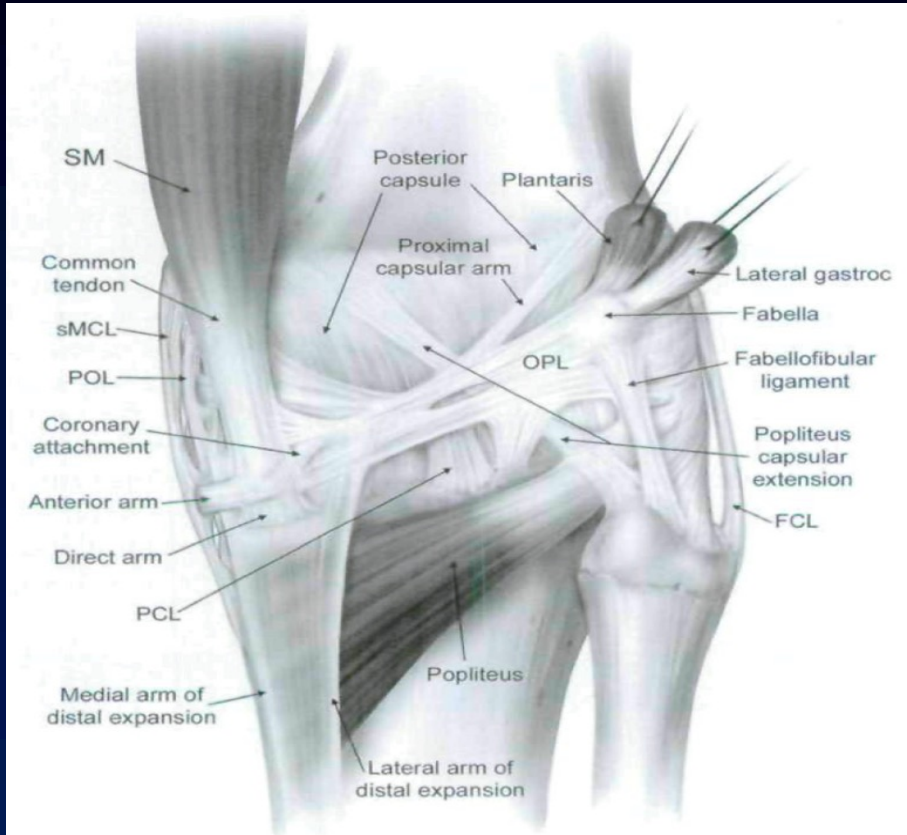
# ARTHROSCOPIC ANATOMY of the POSTERO-MEDIAL COMPARTMENT of the KNEE



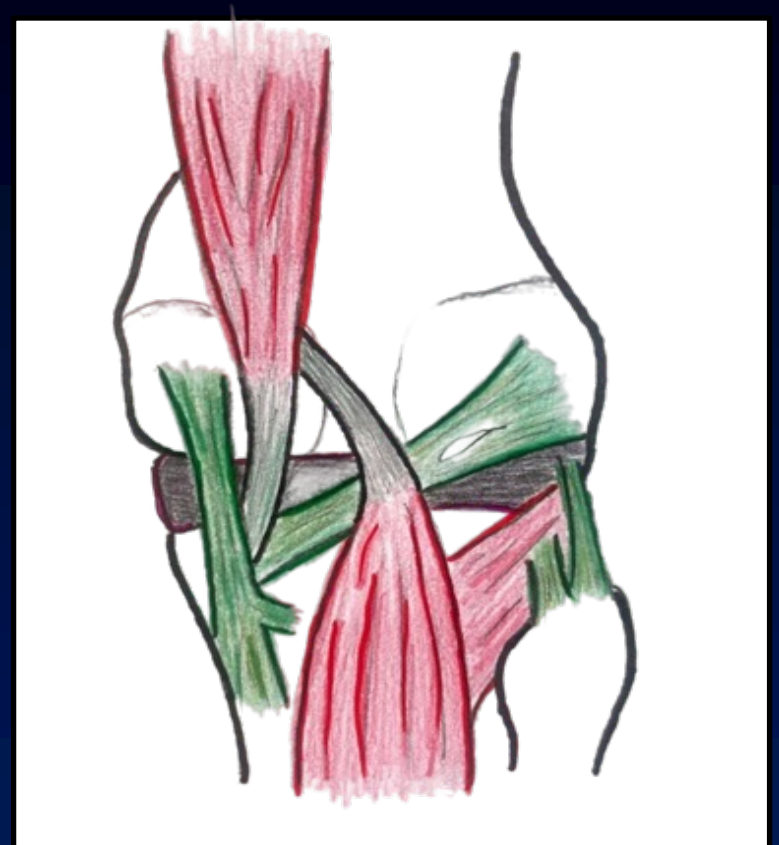
*Fabio Carminati, François Kelberine, Gaspard Fournnier  
Aix en Provence- France*



# Post anatomy of the knee



*LaPrade JBJS 2007*

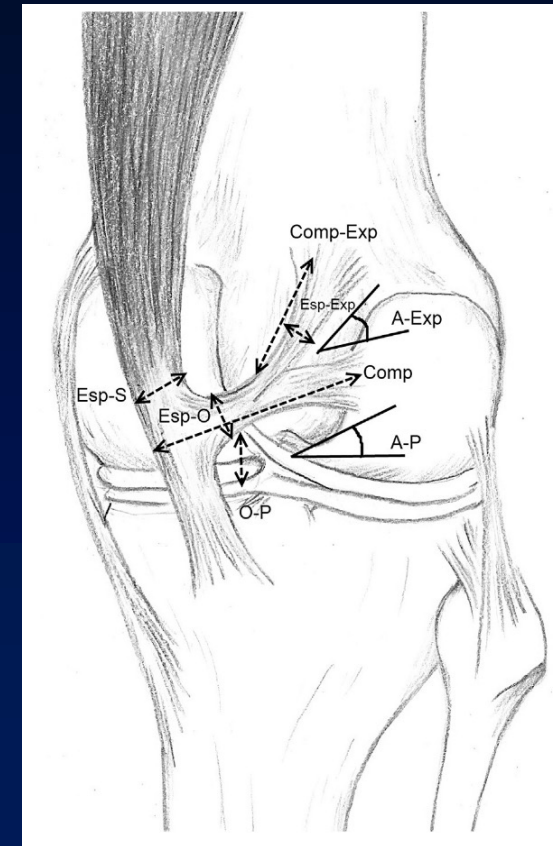
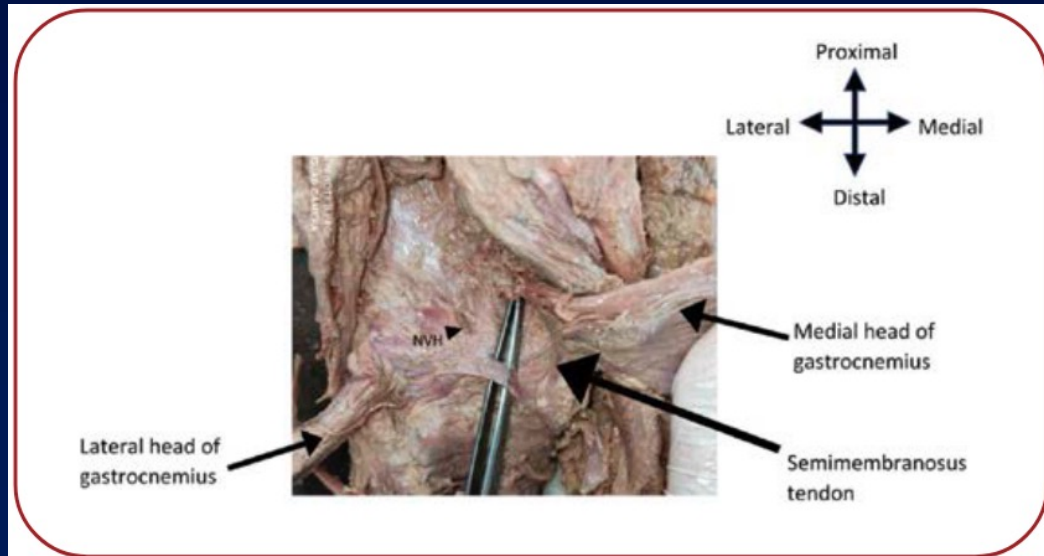


*Fabio Carminati*

**POL (MCL) ≠ OPL**

# OBLIQUE POPLITEUS LIGAMENT

- ✓ Accessory attachment of SM tendon
- ✓ Horizontal bundle
- ✓ tricuspid valve between GM & SM
- ✓ at the origin of poplitear cyst

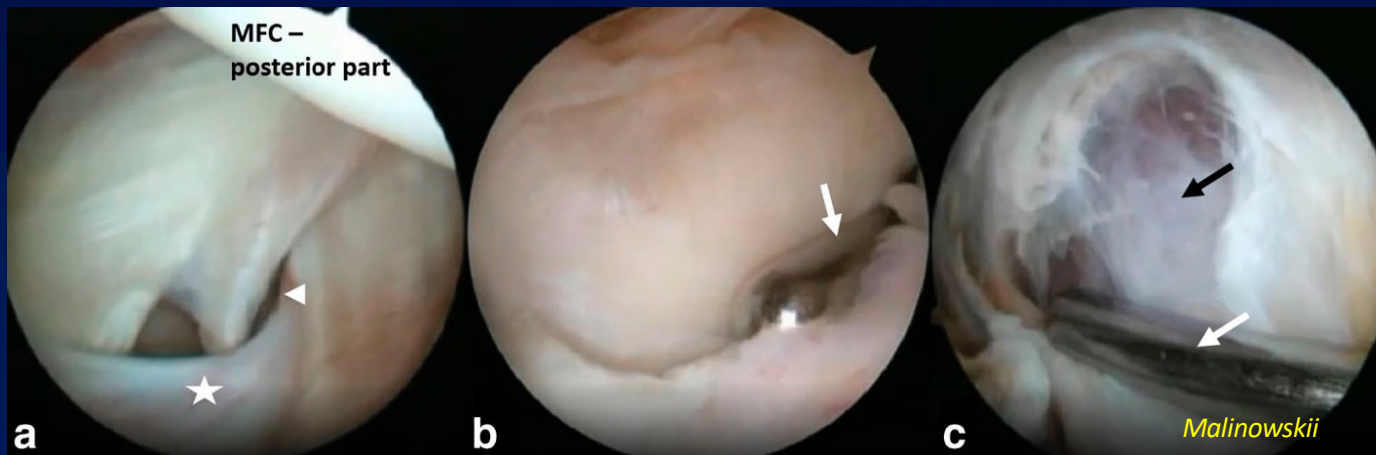


# OBLIQUE POPLITEUS LIGAMENT

- ✓ Included within the post capsule
- ✓ Well recognized since post arthroscopy frequent

- Ramp lesions
- PCL -R
- Synovectomy

Malinowski - SICOT 2023  
Wu - Arthroscopy Techniques 2022  
Li - Arch Orthop Trauma Surg 2021



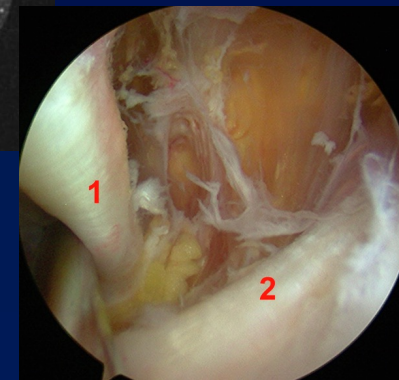
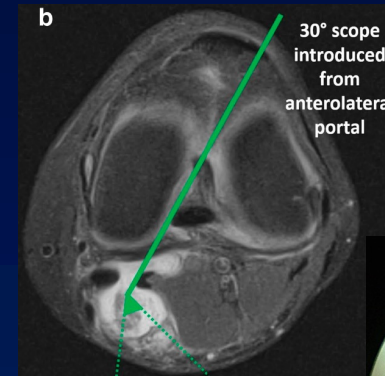
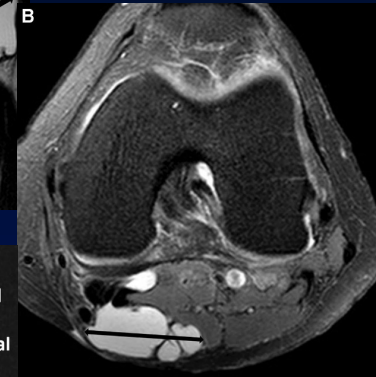
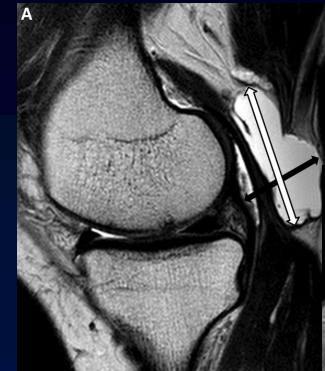
# Prospective anatomical study

- ✓ Continuous study / 3 months
- ✓ 102 knees patients

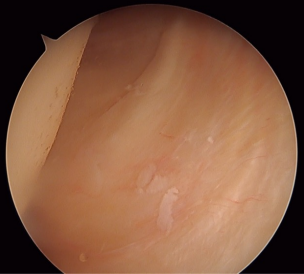
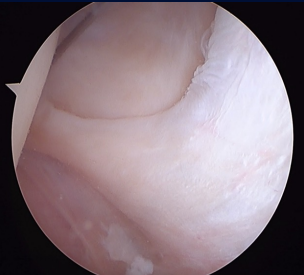
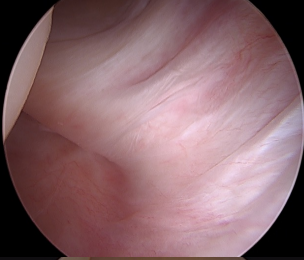
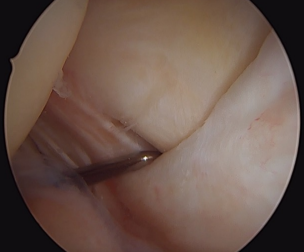
Posterior Arthroscopy for different etiologies

## ✓ Protocol

1. MRI assessemnt pre-op: Cyst? size?
2. Arthroscopic treatment
3. Assesement OPL from AL portal
4. Posteromedial synovectomy when PC is symptomatic



# RESULTS

		Patients	Poplitear cyst	Size (cm <sup>3</sup> )
OPL TYPE 1 Embedded		13 (13,5%)	0 (0%)	
OPL TYPE 2A Cord-Like		22 (22,9%)	2 (9,1%)	7.33 (± 4.93)
OPL Type 2B Normal		40 (41,7%)	6 (15%)	11.33 (± 11.9)
OPL Type 3 bulging		21 (21,9%)	12 (57,1%)	7.9 (± 5.6)
			<b>P &lt; 0,001</b>	<b>P = 0,486</b>

# POSTEROMEDIAL CAPSULE

- ✓ capsular fold?
- ✓ No clear classification

- ✓ Kim 2014: 3 categories
- ✓ Calvisi 2016: 6 categories

- ✓ Anatomical Continuum



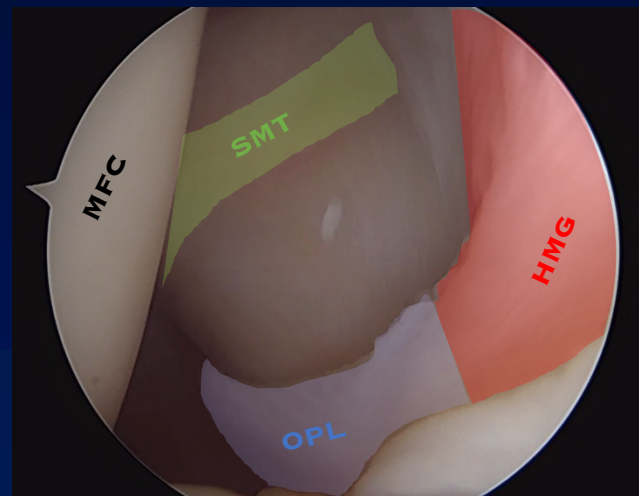
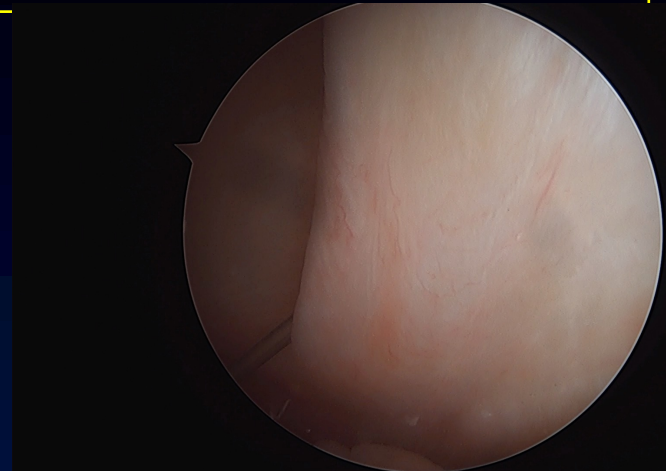
- ✓ OPL bulging => PC or PC => LOP bulging?

# SYNOVECTOMY

- ✓ If symptomatic PC
- ✓ goal: balance pressure between joint and PC
- ✓ decompression

## ✓ TRIANGLE for SYNOVECTOMY

- ✓ OPL = lower landmark
- ✓ Medial gastrocnémius tendon laterally
- ✓ SM Tendon medially





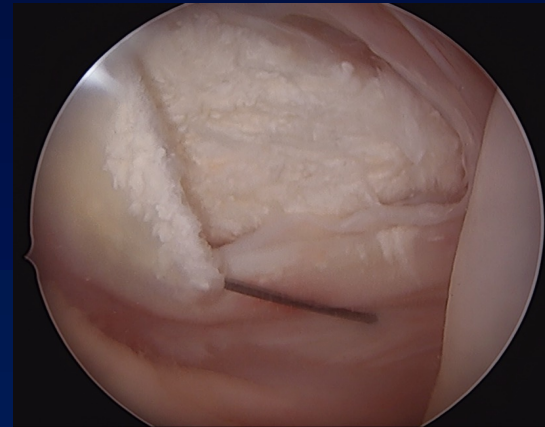
# VARIANTS

## ✓ OPL type 1:

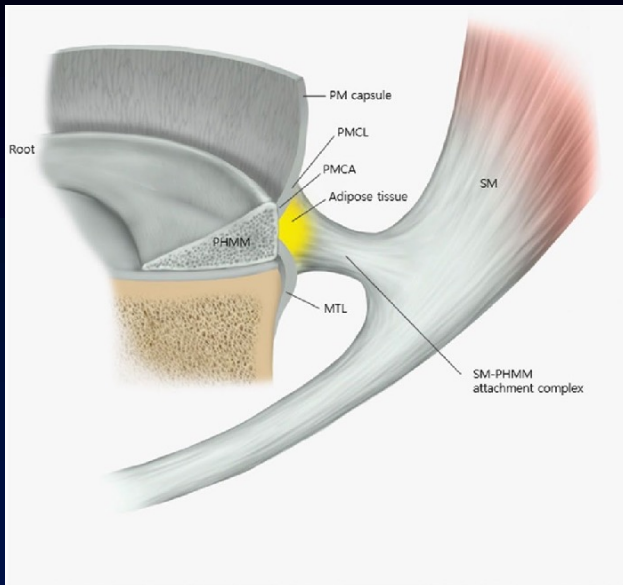
- ✓ Ramp lesions: « fall » of posterior capsule
- ✓ Thick capsule

## ✓ OPL type 3:

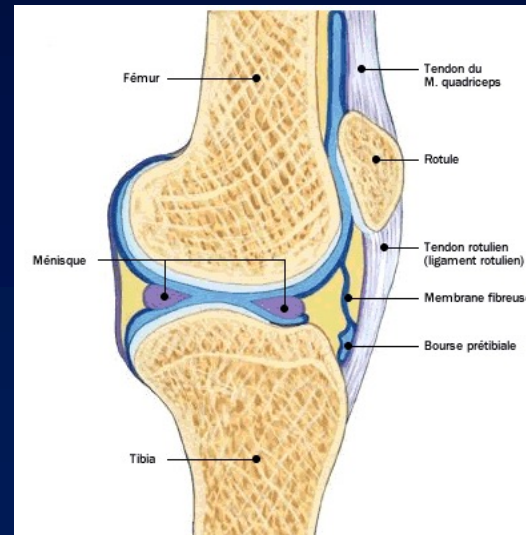
- ✓ Inflammatory pathology
- ✓ Chondrocalcinosis
- ✓ SVNH



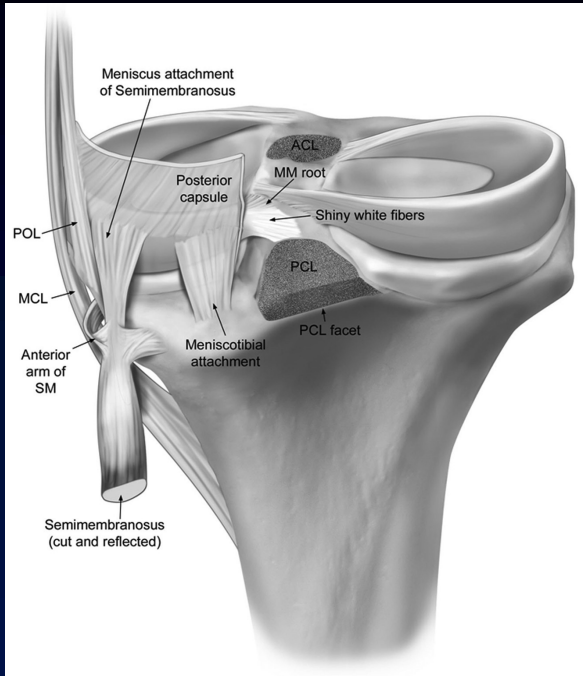
# Posterior medial meniscus



- ✓ Close link capsule /OPL/meniscus
- ✓ Knee always in extension

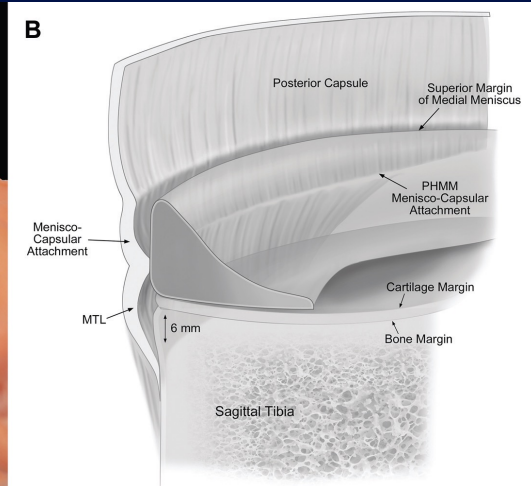
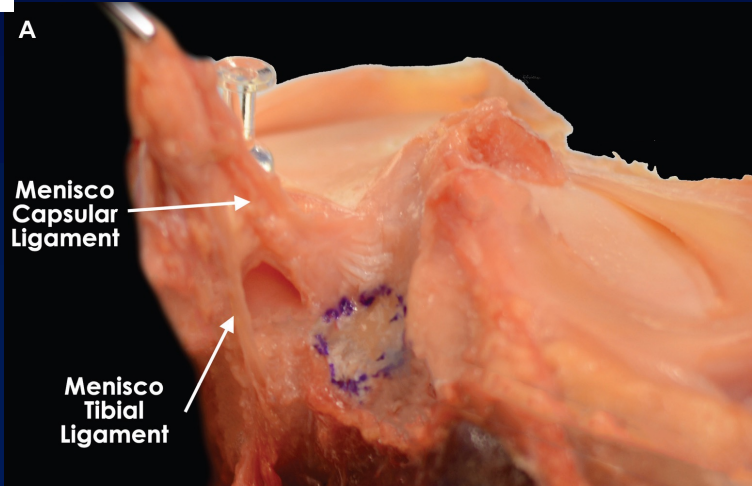


# Posterior medial meniscus



✓ Knee bended @90°

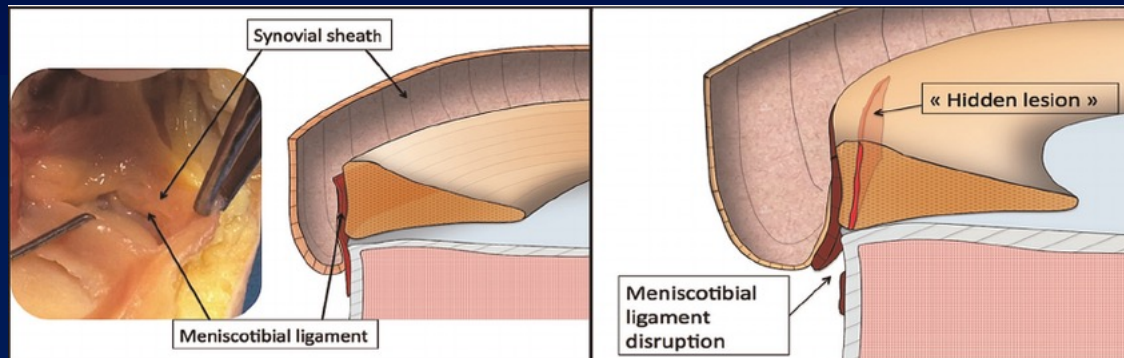
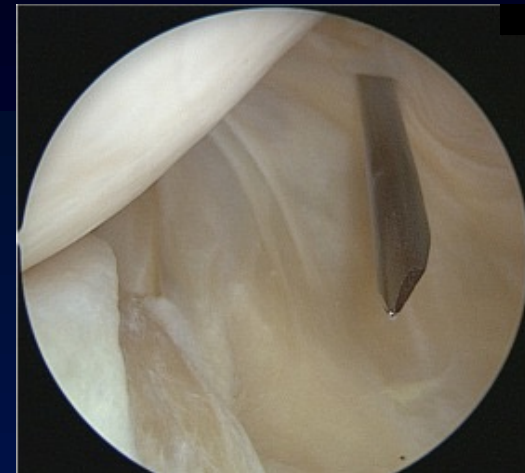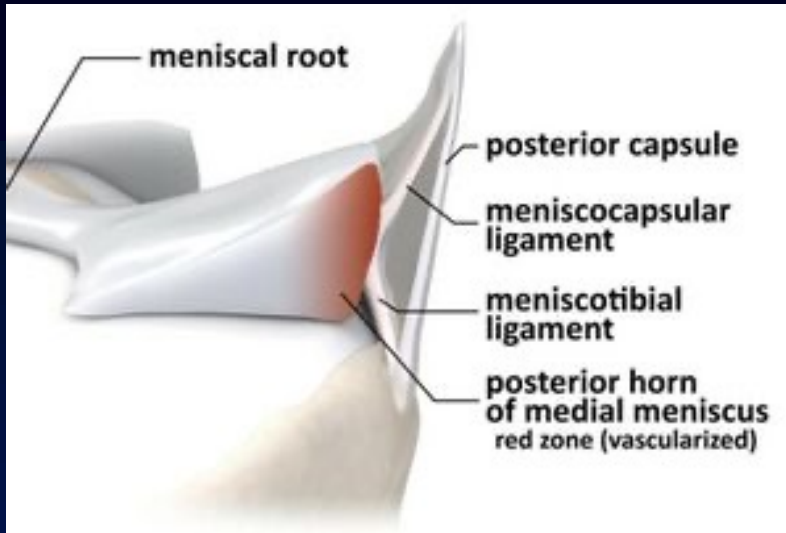
✓ Synovial recess



DePhillipo *AJSM* 2108

✓ Ramp Lesion?

✓ Probing mandatory



Courtesy B. Sonnery-Cottet